DOI: 10.1111/echo.13632

CASE REPORT

WILEY Echocardiography

Protruding coronary stent detected by transesophageal echocardiography changes surgical procedure

David M. Corda MD[1] | Carl Dragstedt DO, FACC[2,3] | Gary S. Allen MD[4] | Gregory M. Janelle MD, FASE[1]

[1]Department of Anesthesiology, University of Florida College of Medicine, Gainesville, FL, USA

[2]Division of Cardiovascular Medicine, Department of Medicine, University of Florida College of Medicine, Gainesville, FL, USA

[3]Veterans Health Administration, Gainesville, FL, USA

[4]Florida Hospital Waterman, Tavares, FL, USA

Correspondence
David M. Corda, Department of Anesthesiology, University of Florida College of Medicine, Gainesville, FL, USA.
Email: dcorda@anest.ufl.edu

Funding information
This research did not receive any specific grant from funding agencies in the public, commercial, or not-for-profit sectors

This case describes an unusual intraoperative transesophageal echocardiogram (TEE) finding of an unknown sinus of Valsalva mass in a patient undergoing an off-pump coronary artery bypass procedure. The intraoperative TEE finding not only revealed a protruding right coronary ostial stent but also changed the surgical procedure to include an aortotomy that allowed successful removal of the stent. As interventional cardiologists begin exploring more techniques to manage difficult ostial lesions, this finding may be seen more commonly in the future. This case highlights how the use of routine TEE even in off-pump coronary artery bypass procedures may be very beneficial.

KEYWORDS
coronary artery bypass graft surgery (CABG), sinus of Valsalva, TEE, transesophageal echocardiography

1 | CASE REPORT

A 70-year-old woman with a known history of coronary artery disease presented for off-pump coronary artery bypass grafting (OPCAB) for unstable angina. The patient had known coronary disease with a right coronary artery (RCA) stent placed 1 year before presentation. Preoperative catheterization revealed multivessel disease including 90% left main ostial stenosis with mid-RCA stenosis. The patient had a transthoracic echocardiogram performed at an outside institution 6 months prior to admission. Although the images were not available for review, the patient was reported to have normal left ventricular and valvular function. The patient's case was expedited to the operating room secondary to her left main stenosis and angina. Preoperative echocardiography was not performed.

After induction of anesthesia, intraoperative transesophageal echocardiography (TEE) revealed a fixed hyperechoic round lesion with an echolucent center measuring 0.7 cm in diameter in the sinus of Valsalva that persisted throughout the cardiac cycle. The lesion was seen in both the mid-esophageal aortic valve short-axis view (Figure 1, Movie S1) and mid-esophageal aortic valve long-axis view (Figure 2, Movie S2) and generated a comet tail artifact in the ME AV SAX view. The mass caused a mild decrease in right coronary cusp excursion. The anesthesia and surgical team decided to change the procedure and perform the bypass grafting under cardiopulmonary bypass to facilitate exploration of the aorta.

Aortotomy revealed a tissue-covered mass protruding 3–4 mm from the RCA ostium (Figure 3). The mass was identified as a protruding coronary stent and was subsequently dissected from the ostium and removed (Figure 4). The patient then underwent a successful 3-vessel CABG revascularization.

2 | DISCUSSION

This report describes a rare echo finding discovered during a planned OPCAB procedure that resulted in a change in surgical procedure. Masses in the sinus of Valsalva are an uncommon occurrence. Possible differential diagnoses include fibroelastoma, lipoma, vegetation, thrombus, artifact, and calcification. Although this finding has been reported in the distant past by Lerner et al.,[1] our case as well

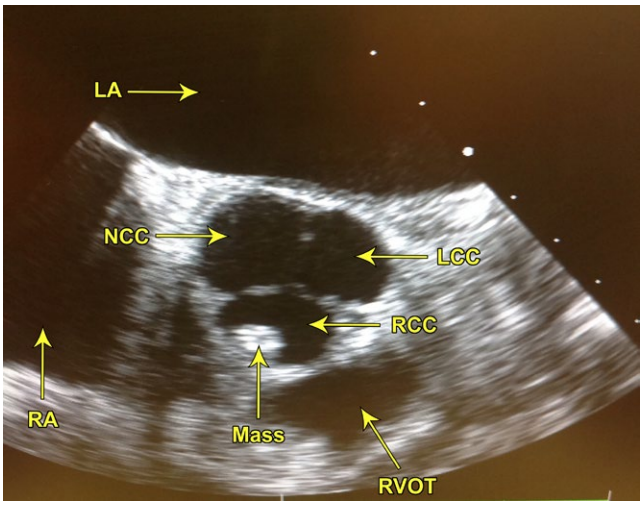

FIGURE 1 Mid-esophageal aortic valve short axis. LA = left atrium; LCC = left coronary cusp; NCC = noncoronary cusp; RA = right atrium; RCC = right coronary cusp; RVOT = right ventricular outflow tract

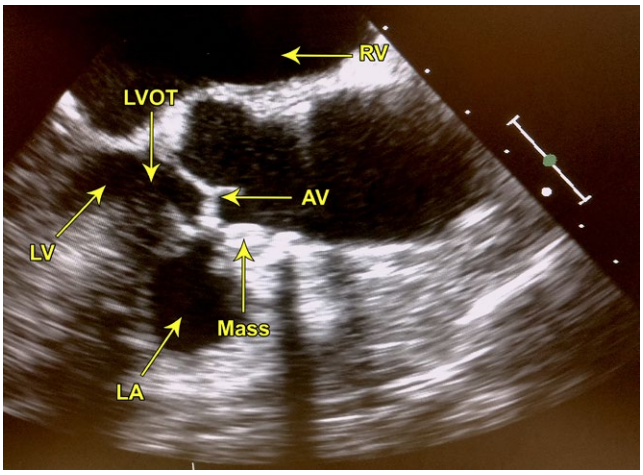

FIGURE 2 Mid-esophageal aortic valve long axis. AV = aortic valve; LA = left atrium; LV = left ventricle; LVOT = left ventricular outflow tract; RV = right ventricle

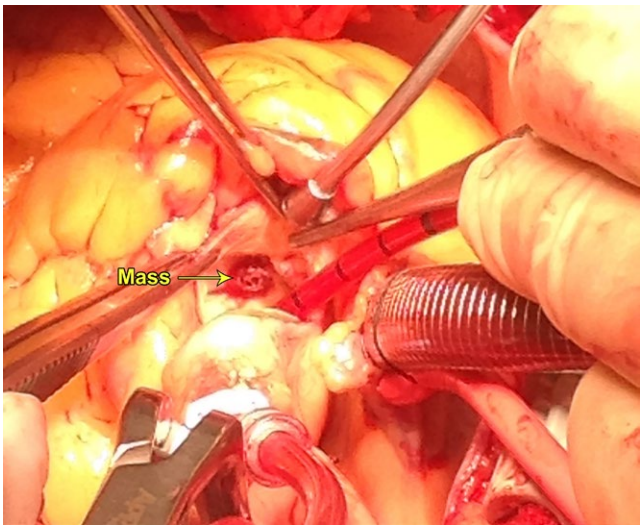

FIGURE 3 Surgically exposed right coronary ostial stent

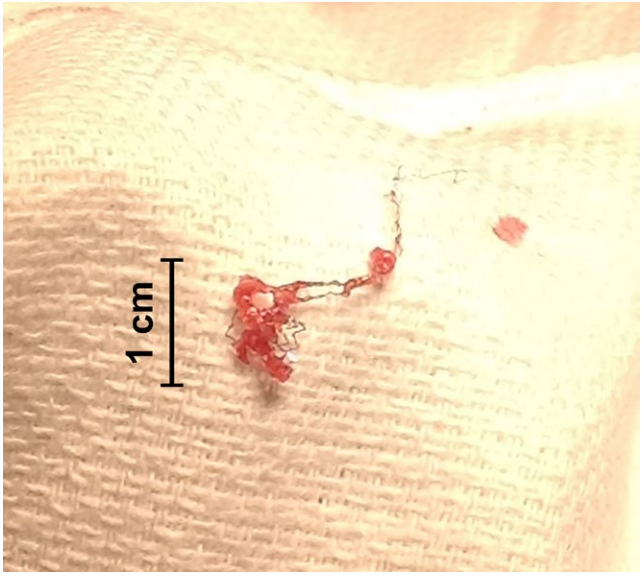

FIGURE 4 Removed right coronary ostial stent

as a more recent report[2] lead us to believe that the incidence of discovery of protruding coronary ostial stents during perioperative TEE will become more common as interventional cardiology procedures become more advanced. Aorto-ostial coronary artery lesions, defined as lesions of >50% stenosis within 3 mm of the coronary ostium, represent a challenging subset of obstructive diseases encountered by interventional cardiologists in contemporary practice. As was true in this case, the prevalence of aorto-ostial coronary artery lesions is greater in the right than the left coronary artery. Optimal deployment of coronary stents in the aorto-ostial landing zone faces various procedural challenges and unique lesion-specific characteristics, including nontubular aorto-ostial anatomy, variable coronary takeoff angulation from aorta, and confluent calcification extending from the aorto-ostial complex. Perhaps the most vexing procedural challenge lies in the inability to visualize "normal" coronary segments proximal and distal to the lesion. Interventionalists rely on orthogonal angiographic imaging and use of techniques such as nonselective contrast media injection and identification of the aorto-ostial plane using aortic calcification as a landmark. However, the potential for so-called stent geographic miss still remains, as evidenced by this case. To overcome these obstacles, various interventional procedural techniques have been utilized with variable successs.[3] In addition, devices specific for aorto-ostial coronary artery lesion, such as the Ostial Pro system (Merit Medical Systems Inc, South Jordan, UT, USA), have been developed to help the proceduralist overcome the limitations of 2D angiography by way of device-guided positioning of the stent delivery system at the true aorto-ostial plane.

Protruding ostial stents pose multiple risks to patients. Although rare, intra-aortic protrusion of a stent has led to acute perforation of a coronary cusp, severe aortic insufficiency, and pulmonary edema.[4] Furthermore, stents protruding into the aorta are under increased

strain and more likely to fracture and embolize. Fracture of ostial stents with peripheral embolization can cause limb ischemia.[5] Another serious complication of protruding stent fracture is embolism into the carotid artery or cerebral circulation.[6,7]

While the use of intraoperative TEE has become relatively commonplace in patients undergoing on-pump cardiac surgery, the routine use of TEE in OPCAB procedures is sporadic. This trend in practice is likely secondary to frequent surgical manipulation of the heart during OPCAB procedures that may render TEE imaging planes inadequate. However, even intermittent TEE views of the heart during OPCAB procedures may discern etiologies for hemodynamic instability. Positional mitral regurgitation secondary to surgical manipulation of the heart,[8] myocardial ischemia, hypovolemia, and extrinsic cardiac compression from surgical stabilizers on the heart can all cause intraoperative hypotension. In our case, the use of TEE found an unexpected mass that changed the surgical procedure and led to a better outcome for the patient. This case highlights an unusual sight to echocardiographers and is another example in support of the use of TEE in even routine OPCAB procedures.

CONFLICT OF INTEREST

None.

REFERENCES

1. Lerner A, Subramaniam B, Mahmood F, Khabbaz KR. An unusual echodensity in the ascending aorta: transesophageal echocardiographic visualization of a protruding coronary stent. *Anesth Analg*. 2006;103:854–855.
2. Rabia A, Lu Y, Robina M, Mahmood F. An echodensity in the sinus of Valsalva. *J Cardiothorac Vasc Anesth*. 2016;30:1742–1743.
3. Jaffe R, Halon D, Shiran A, Rubinshtein R. Percutaneous treatment of aorto-ostial coronary lesions: current challenges and future directions. *Int J Cardiol*. 2015;186:61–66.
4. Quintana E, Mestres CA, Congiu S, Josa M, Cartañá R. Delayed aortic regurgitation caused by a right coronary stent protruding into the aorta. *J Heart Valve Dis*. 2009;18:717–719.
5. Siani A, Siani LM, Mounayergi F, Baldassarre E. Lower limb ischemia after migration of a coronary artery stent into the femoral artery. *Interact Cardiovasc Thorac Surg*. 2008;7:447–448.
6. Mamopoulos A, Nowak T, Klues H, Luther B. Late coronary ostial stent fracture and embolism causing an acute thrombotic occlusion of the carotid artery with cerebral infarction. *Circ Cardiovasc Interv*. 2012;5:e76–e78.
7. Immer FF, Heller G, Dick F, Carrel TP. Fractured and embolized coronary stent mimicking significant internal carotid stenosis. *Ann Thorac Surg*. 2006;82:739–740.
8. Ozay B, Sargin M, Abay G, et al. The severity of positional mitral regurgitation during off-pump coronary artery bypass grafting. *Heart Surg Forum*. 2008;11:E145–E151.

SUPPORTING INFORMATION

Additional Supporting Information may be found online in the supporting information tab for this article.

Movie S1. Movie of Figure 1 in mid-esophageal aortic valve short axis shows mass behind right coronary cusp. LA = left atrium; LCC = left coronary cusp; NCC = noncoronary cusp; RA = right atrium; RCC = right coronary cusp; RVOT = right ventricular outflow tract.
Movie S2. Movie of Figure 2 in mid-esophageal aortic valve long axis shows mass in sinus of Valsalva. AV = aortic valve; LA = left atrium; LV = left ventricle; LVOT = left ventricular outflow tract; RV = right ventricle.

How to cite this article: Corda DM, Dragstedt C, Allen GS, Janelle GM. Protruding coronary stent detected by transesophageal echocardiography changes surgical procedure. *Echocardiography*. 2017;00:1–3. https://doi.org/10.1111/echo.13632